



Ram Nawal Rao^{1*}, Sanjay Kannaujia² and Paramita Paul²

¹Department of Pathology, Additional Professor, Sanjay Gandhi Postgraduate Institute of Medical Sciences, Lucknow 226011, UP, India

²Department Pathology, Senior Resident, Sanjay Gandhi Postgraduate Institute of Medical Sciences, Lucknow 226011, UP, India

Dates: Received: 31 January, 2017; Accepted: 09 February, 2017; Published: 10 February, 2017

*Corresponding author: Ram Nawal Rao, Department of Pathology, Sanjay Gandhi Postgraduate Institute of Medical Sciences, Rae Bareilly Road, Lucknow, 226014, India. Tel: 08004904564, Email: rnrao@sgpgi.ac.in; rnawalrao@gmail.com

Keywords: Rhabdomyosarcoma; Prostate; Primary; Immunohistochemistry

<https://www.peertechz.com>

Case Report

Primary Spindle Cell Rhabdomyosarcoma of Prostate: A Case Report with Review of Literature

Abstract

Primary spindle cell rhabdomyosarcoma of the prostate is an uncommon variant of embryonal rhabdomyosarcoma seen in pediatric age group mostly during infancy and childhood. Rhabdomyosarcoma (RMS) arising from prostate predominantly presents obstructive urinary symptoms. To date, only one case of the spindle cell variant of embryonal rhabdomyosarcoma of the prostate have been described in literature. The delay in diagnosis and a more aggressive behavior of this malignancy contributed to an eventually unfavorable outcome. Early diagnosis and complete surgical resection offering patients for the best possibility of survival.

Introduction

Primary spindle cell rhabdomyosarcoma is unusual malignant tumor, present generally early in age with lower urinary tract symptoms [1,2]. This rare spindle cell variant of embryonal rhabdomyosarcoma presenting urinary obstructive problems, it should be considered in a differential diagnosis of spindle cell lesions of prostate when it presents in pediatric age groups. Patient visited three times to outpatient department after confirmed diagnosis, he referred to radiotherapy department for chemotherapy and further management.

Case Report

A 13-year-old male presented with constipation, intermittent fever, irritative and obstructive lower urinary tract symptoms since two months. No history of hematuria, stone disease and pyuria. No history of lymphadenopathy and organomegaly was seen in the patient. Investigations showed normocytic normochromic anemia, hypercalcemia and hyperuricemia. Routine urine examination was normal. No laboratory evidence of tuberculosis, immuno-ompromised state or an autoimmune disorder was observed. Bilateral testes were normal. Digital rectal examination showed enlarged prostate with smooth surface and firm to hard in consistency. He was admitted with diagnosis of a prostatic mass. The serum level of prostate-specific antigen (PSA) was within the normal range (0.04 ng/ml). The prostatic acid phosphatase (PAP) were also within normal limits. Computed tomography of prostate showed homogenous soft tissue mass measuring 4x5cm in size

(Figure 1). Multiple tru-cut core needle biopsies from different areas of prostate was done.

Histopathological Examination

The sections from multiple cores of biopsy from different site of prostate showed an infiltrating tumour composed of predominantly spindle shaped cells with high N:C ratio, hyperchromatic elongated nuclei, condensed chromatin, inconspicuous nucleoli and scanty to moderate eosinophilic cytoplasm. Few mitotic figures, myxoid changes and large areas of necrosis is seen (Figure 2). Section from right apex shows only muscles and closely packed benign glands.

Immunohistochemistry

On immunohistochemistry tumor cells were strongly positive for myogenin (Figure 3), desmin, vimentin (Figure 4) and S100. The tumour cells are negative for CD117, SMA,

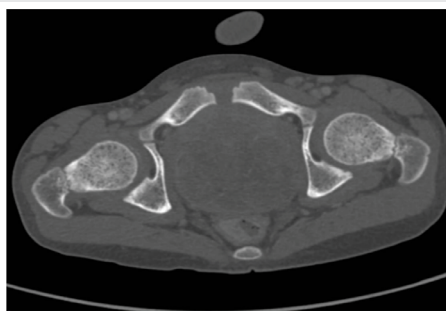


Figure 1: Computed tomography of prostate showed homogenous soft tissue mass measuring 4x5cm in size (arrow).

CD-99, CK, ALK1, Synaptophysin, NSE, EMA, HMB45 and LCA. Histopathology and immunohistochemistry findings are consistent with diagnosis of spindle cell rhabdomyosarcoma of prostate.

The patient is well after 8 months of follow –up and confirm diagnosis, no recurrence is seen.

Discussion

Prostatic rhabdomyosarcoma spindle cell subtype is recently described rare variant of embryonal RMS that occurs predominantly in male infants and children with median age of 5 years. Only sporadic cases have been reported in non-pediatric age group [1,2]. Prostate sarcoma accounted

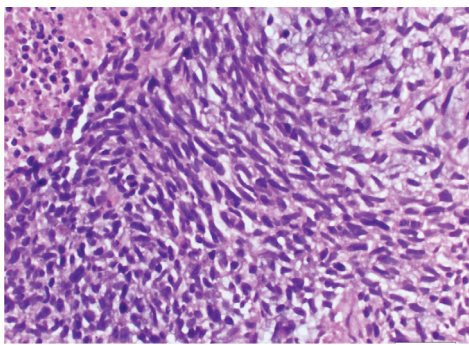


Figure 2: Section showed tumor composed of sheets of spindle shaped cells along with areas of necrosis and hemorrhage. Spindle cells have hyperchromatic elongated nuclei, condensed chromatin, inconspicuous nucleoli and scanty to moderate eosinophilic cytoplasm (H & E x400 magnification).

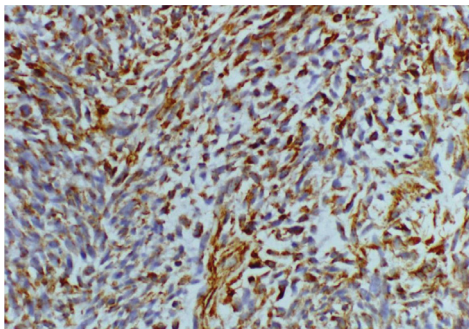


Figure 3: Myogenin is strongly positive in tumor cells.

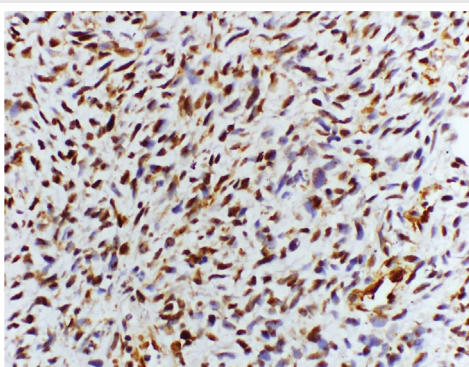


Figure 4: Vimentin is strongly positive in tumor cells.

For 3.21% of all the prostatic malignant tumors, the average age was 39.5 years old ranging from 17 to 62 years [3]. Patients with rhabdomyosarcoma showed rapidly progressive obstructive urinary symptoms, progressively worsening dyspnea on exertion and onset of skin nodules with polyarthralgias and low grade fever [4], smooth and firm enlargement of prostate on digital rectal

examination, occasional suprapubic mass, regional lymph node spread, respiratory symptoms due to metastasis to lungs, osteoclastic bone metastases, and normal prostatic acid phosphates and prostate specific antigen levels [1,2].

Spindle cell lesions of prostate displayed diagnostically challenging and encompass a broad array of benign and malignant neoplastic lesions. The differential diagnosis of spindle cell rhabdomyosarcoma are lesions arises only within the prostate and generally represents entities that originate from the prostate epithelium or stroma, such as sclerosing adenosis, sarcomatoid carcinoma, stromal tumors of uncertain malignant potential (STUMP), stromal sarcoma, solitary fibrous tumor, leiomyosarcoma, inflammatory myofibroblastic tumour, gastrointestinal stromal tumour, fibrosarcoma and malignant peripheral nerve sheath tumour (Table 1). The recognition of rhabdomyoblasts in tumors are better differentiated to the pathologist as direct correct diagnosis. In more primitive tumors, immunohistochemistry for skeletal muscle specific markers, such as myogenin, myo-D1 and desmin can help to identify the confirm diagnosis as rhabdomyosarcoma [5].

Tumor debulking (excising $\geq 50\%$ of tumor) followed by chemotherapy has improved overall survival rates to 75% in RMS patients especially in embryonal RMS but some patient had distant detectable spread at the time of presentation which precluded any form of surgical intervention [6]. A retrospective study in 25 patients with genitourinary RMS (15 bladder/10 prostate), the median age at diagnosis was 4 years, radical surgery and urinary diversion were performed. Urinary diversion comprised 2 continent anal diversions, 11 continent cutaneous diversions, 4 colon conduits and 2 urethral diversions (2 + 3 years of age). In the younger child with urethral diversion, a cutaneous appendix stoma was additionally constructed in case of inability to void spontaneously [7].

Advanced 3-Tesla imaging and MRI/TRUS-fusion biopsies in children are feasible and represent an effective tool to examine suspicious pelvic lesions. Depending on histology, this can lead to a significant reduction of therapy-associated morbidity [8]. Although primary site in prostate is a favorable prognostic sign for rhabdomyosarcomas, the presence of detectable metastases, tumor size > 5 centimeters and age > 10 years at presentation were the associated poor prognostic features in patient which explains the unfortunate outcome [9]. As in younger patients, embryonal subtype is the predominant pattern. In contrast to the relatively good prognosis for treated rhabdomyosarcoma in children, the prognosis in adults is poor with most dying of disease in < 2 years, despite multimodality therapy. In part, the dismal prognosis is due to delayed presentation and extensive spread of disease. Patient initially presenting with obstructive micturition problems, perineal pain

Table 1: Immunohistochemical findings in differential diagnosis of spindle cell lesions in prostate.

Types of tumors	Immunohistochemical findings										Molecular Analysis
	VIM	CD34	S100	SMA	DES MIN	MYO GENIN	BCL2	CD117	ALK1	CK	
Spindle cell variant of Rhabdomyosarcoma	++	-	+/-	-	++	++	-	-	-	-	
Fibrosarcoma	++	-	-	-	-	-	-	-	-	-	
Solitary fibrous tumor	+/-	+	-	-	-	-	+	-	-	-	
Leiomyoma Leiomyosarcoma	+	-	-	++	+/-	-	-	-	-	-	MD-M2 and CDK4 mutations
Schwannoma/MPNST	+/-	+/-	++	-	-	-	-	-	-	-	
Gastrointestinal stromal tumor	++	++	+/-	-	-	-	-	++	-	-	c-KIT or PDGFRA mutations
Fibrohistiocytic tumor	+	+	-	-	-	-	-	-	-	-	
Inflammatory myofibroblastic tumor	+	-	-	+	-	-	-	-	++	-	ALK1 mutations
Sarcomatoid carcinoma	+/-	-	-	-	-	-	-	-	-	++	

and night sweat. After diagnosis by transrectal biopsy of the prostate, radiochemotherapy within the CWS 2002 P study was applied: nine cycles of vincristine, doxorubicin, actinomycin D, ifosfamide, and fractionated radiotherapy of the tumor and suspect lymph nodes (final dose 50.4Gy). "The tumor initially shrank, but an early local recurrence arose. Second-line chemotherapy was applied, followed by a salvage radical cytoprostatectomy. The patient died of disseminated disease 14 months after diagnosis [10]. Refers in patient 1. Surgery is the mainstay of treatment in spindle cell rhabdomyosarcoma.

Conclusion

Spindle cell variant of embryonal rhabdomyosarcoma in pediatric age group may be considered in differential diagnosis of prostatic sarcomas when the patient displaying urinary outlet obstruction and aggressive behaviour. It is careful to have a high index of suspicion in diagnosing such case early to prevent worse prognosis.

References

- Nabi G, Dinda AK, Dogra PN (2002) Primary embryonal rhabdomyosarcoma of prostate in adults: diagnosis and management. *Int Urol Nephrol* 34: 531-534. [Link: https://goo.gl/votnpW](https://goo.gl/votnpW)
- Dalal DD, Tongaonkar HB, Krishnamurthy S, Kulkarni JN (2000) Embryonal rhabdomyosarcoma of prostate in an adult a diagnostic dilemma *Indian J Cancer* 37: 50-53. [Link: https://goo.gl/4JPLk5](https://goo.gl/4JPLk5)
- Chen HJ, Xu M, Zhang L, Zhang YK, Wang GM (2005) Prostate

sarcoma: a report of 14 cases *Zhonghua Nan Ke Xue* 11: 683-685. [Link: https://goo.gl/bnyTWn](https://goo.gl/bnyTWn)

- Singh NK, Malatesha G, Vineet G, Mohan A (2009) Embryonal prostatic rhabdomyosarcomas disguised presentation in an adolescent male: a case report *Cases Journal* 2: 7546. [Link: https://goo.gl/7OYiZh](https://goo.gl/7OYiZh)
- Hansel DE, Mehsati H, Elizabeth M, Jonathan I Epstein (2007) Spindle cell lesions of the adult prostate *Modern Pathology* 20:148-158. [Link: https://goo.gl/NPG0QH](https://goo.gl/NPG0QH)
- Raney RB, Stoner JA, Walterhouse DO, Andrassy RJ, Donaldson SS, et al. (2004) a report from The Intergroup Rhabdomyosarcoma Study-IV 1991-1997. *Pediatr Blood Cancer* 42: 618-625. [Link: https://goo.gl/qg7GN1](https://goo.gl/qg7GN1)
- Stein R, Frees S, Schröder A, Russo A, Gutjahr P, et al. (2013) Radical surgery and different types of urinary diversion in patients with rhabdomyosarcoma of bladder or prostate - A single institution experience *J Pediatr Urol* 15-16. [Link: https://goo.gl/XpdgiZ](https://goo.gl/XpdgiZ)
- Kuru TH, Roethke MC, Nyarangi-Dix J, Okouoyo S, Stockklausner C, et al. (2013) Pediatric case report on magnetic resonance imaging/transrectal ultrasound-fusion biopsy of rhabdomyosarcoma of the bladder/prostate: a new tool to reduce therapy-associated morbidity? *Urology* 81: 417-420. [Link: https://goo.gl/Q8Xt0M](https://goo.gl/Q8Xt0M)
- Raney RB, Anderson JR, Barr FG, Donaldson SS, Pappo AS, et al. (2001) Rhabdomyosarcoma and undifferentiated sarcoma in the first two decades of life: a selective review of intergroup rhabdomyosarcoma study group experience and rationale for Intergroup Rhabdomyosarcoma Study V *J Pediatr Hematol Oncol* 23: 215-220. [Link: https://goo.gl/G53rEs](https://goo.gl/G53rEs)
- Stefan Latz, Jörg Ellinger, Diane Goltz, Christian Marx, Ivo Leuschner, et al. (2013) Spindle cell rhabdomyosarcoma of the prostate. *Int J Urol*. [Link: https://goo.gl/J8aGcd](https://goo.gl/J8aGcd)